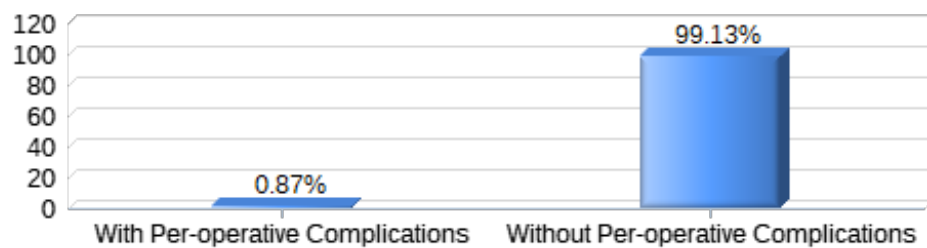




EAC-BS

Per-operative complications

Complications		Percentage
1	Bleeding	250/61462 0.41 %%
2	Gastrointestinal Perforation	89/61462 0.14 %%
3	Liver Injury	68/61462 0.11 %%
4	Major Vessel Injury	5/61462 0.01 %%
5	Splenic Injury	42/61462 0.07 %%
6	Other	104/61462 0.17 %%
7	Death	2/61462 0.00 %%



Status	Total
With Per-operative Complications	537
Without Per-operative Complications	60,925
<i>Total: 61,462</i>	

Other Per-operative complications analysis

Sum	Details
1	3 weken na OK, moeizaam herstel. 29-1 - 06-2 opgen
1	aabdominal pain with Re LSK
1	abortion of the bariatric procedure
1	abscess
1	Adhesion of the Omentum with small bowel to the an
1	adhesions

-
- 1 Anaesthesia awareness
 - 1 anaphylactic shock
 - 1 anaphylactic shock (Cefacidal)
 - 1 anastomotic dehiscence,pleuric effusion
 - 1 anastomotic leak
 - 1 anesthesia awareness
 - 1 aspiration pneumonia
 - 1 atelectasis left lower zone
 - 1 Atrial fibrillation
 - 1 biliary leakage from cystic duct after cholecystec
 - 1 Bleeding at single site over the distal sleeved st
 - 1 Bleeding from sleeved stomach controlled via clip,
 - 1 Bleeding from the proximal 1/3 of sleeve stomach s
 - 1 bleeding trocar site
 - 1 bronchospasme
 - 1 CO2 embool
 - 1 collaps
 - 1 dehydration
 - 1 Dilated stomach
 - 1 Emoperithoneo from not determined cause
 - 1 ESOPHGEAL PORFORATION
 - 1 Extensive adhesiolysis (previous open splenectomy)
 - 1 Failed Extubation
 - 1 fever
 - 1 FISTULA
 - 1 forgot bac off nazogastric tube. Cut at first stap
 - 1 gastric fistula
 - 1 gecompliceerd door nabloeding waarvoor relaparosco
 - 1 Gecomplieerd postoperatief beloop. In dec opnieuw
 - 1 GIST tumor
 - 1 Good sleeved stomach, Bowel by passed 1.5 - Smal
 - 1 hematoma
 - 1 hernia complications
 - 1 high Blood Pressure
 - 1 High tension and tachycardy
 - 1 hypotension
 - 1 Hypotension and bradycardia during start of proced
 - 1 Hypotension, respiratory insufficiency
 - 1 impaction stapler esophageal
-

1 INCARCERACION PARCIAL DEL ASA INTESTINAL EFERENTE

1 Inflammatory adhesions involving greater omentum,

1 Jejunal anastomosis obstruction

1 jejunal defect, sutured

1 leak

1 leak meckel's diverticulum excision

1 leucocytosis

1 malignancy

1 metilen blue extravasacion

1 Mevrouw is 11-12-13 ontslagen uit het zhuys, maar

1 Mild gastrojejunal anastomosis stricture

1 Minimal oozing at both sleeved and remnant stomach

1 minor liver laceration with trocar

1 minor vessel injury during over-sewn of the excisi

1 naadlekkage

1 nausea and vomiting

1 ng tube cut at the stapler line

1 OK gecompliceerd door sepsis ten gevolge een perfo

1 Oozing from the sleeve stomach at mid 1/3 area cli

1 Oozing over the sleeved stomach and proximal 1/3 o

1 partieel stapling defect

1 Passage stoornis

1 perforation proximal Sleeve - oversewing

2 perigastric abscess

1 Pneumothorax

1 pneumothorax left

1 positive leak test

1 Pulmonary Oedema

1 pulmonary disease

1 Pylorusstenosis

1 Re Ok geen bleeding

1 redo gastro-jejunosomy

1 Respiratory

1 respiratory failure

1 respiratory infection

1 serosa disruption where 2 nd stapler launched

1 serosa injury

2 Serosa Lesion Small Bowel

1 small bleeding mesenterium by Verresneelde

- 1 small hematoma above the excision line
- 1 Small spurter at the incisura level at sleeved and
- 1 splenectomy
- 1 Spurter from the edge of the sleeved and remnant s
- 1 stapler failing
- 1 Stapling mishap G-J anastomosis
- 1 stenosis of the remnant stomach
- 1 Supraventricular tachycardia intra op
- 1 tacycardie
- 1 Tear Mid esophageus
- 1 tissues very fragile, easy to damage, due to tensi
- 1 tracheostomy
- 1 TROCAR SITE BLEEDING
- 1 Trocar site infection
- 1 umbilical wound healing disorder
- 1 Urine retension - home with urinary catheter
- 1 vomiting
- 1 vomiting episodes